
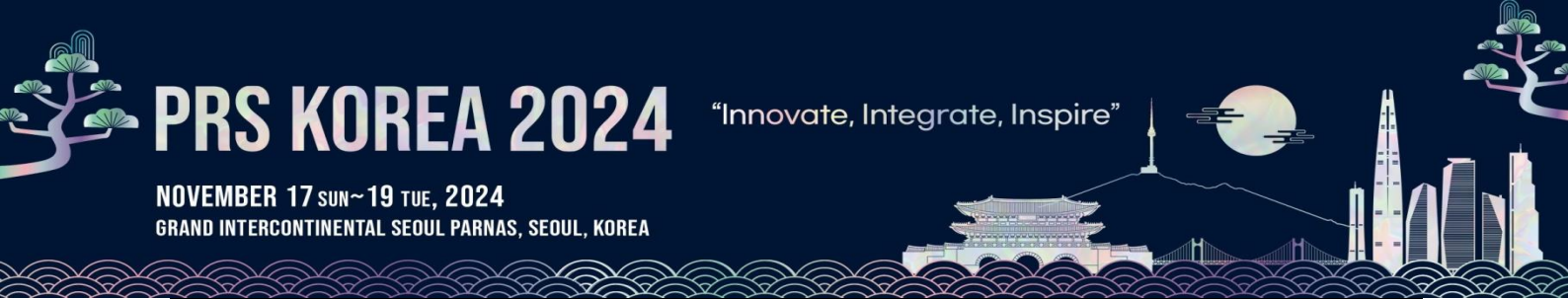

Curriculum Vitae

Personal Information		
Title (i.e. Pf., Dr., etc.)	Dr.	
Name (First name_Middle name_Last name)	Yuki Sasaki	
Degree (i.e. MD, Msc, PhD, etc.)	MD	
Country	Japan	
Affiliation	Hokkaido University	
Educational Background		
<p>2021-present Ph.D. in Faculty of Medicine, Hokkaido University, Sapporo</p> <p>2009-2015 M.D. in Faculty of Medicine, Hokkaido University, Sapporo</p>		
Professional Experience		
<p>2022-present Medical Staff in Hokkaido University, Sapporo, Hokkaido</p> <p>2021-2022 Medical Staff in Tonan Hospital, Sapporo, Hokkaido</p> <p>2019-2022 Medical Staff in Hokkaido University Hospital, Sapporo, Hokkaido</p> <p>2019 Medical Staff in Obihiro-Kosei General Hospital, Obihiro, Hokkaido</p> <p>2018-2019 Medical Staff in Hakodate Central General Hospital, Hakodate, Hokkaido</p> <p>2018 Medical Staff in Sapporo City General Hospital, Sapporo, Hokkaido</p> <p>2017 Medical Staff in Teine Keijinkai Hospital, Sapporo, Hokkaido</p> <p>2015-2017 Junior Resident in Hakodate Central General Hospital, Hakodate, Hokkaido</p>		
Professional Organizations		
<p>Japan Society of Plastic and Reconstructive Surgery (JSPRS)</p> <p>Japan Society for Surgical Wound Care</p> <p>Japan Society of Cranio-Maxillo-Facial Surgery</p>		



Main Scientific Publications

1. Sasaki Y, Ishikawa K, Hatanaka KC, et al. Targeted next-generation sequencing for detection of PIK3CA mutations in archival tissues from patients with Klippel-Trenaunay syndrome in an Asian population. *Orphanet J Rare Dis.* 2023;18(1):270.
2. Sasaki Y, Sakuhara Y, Sasaki S, Maeda T, Yamamoto Y, Ishikawa K. Intranodal lymphangiography with lipiodol as a diagnostic and therapeutic approach for spontaneous cervical chyle leak. *Clin Case Rep.* 2023;11(12):e8161.
3. Sasaki Y, Ishikawa K, Miura T, Funayama E, Yamamoto Y, Maeda T. Partially involuting congenital hemangioma with pyogenic granuloma-induced rapid progression following incisional biopsy in infancy: A case report. *Clin Case Rep.* 2023;11(10):e7941.
4. Sasaki Y, Sasaki S, Ishikawa K. Lingual Arteriovenous Malformation With Bleeding Treated With Polidocanol Foam Sclerotherapy Using Intestinal Forceps to Control Blood Flow. *J Craniofac Surg.* 2022;33(3):e292-e293.

